



Histological Assessment for the effect of deodorant blocker on the blood cells of albino rat

Ayad H. Ebrahem¹, Firas Abbas¹, Enass Mohannad²

¹ Department of Anatomy and Histology, College of Veterinary Medicine, University of Tikrit, Iraq

² Veterinary Teaching Hospital, Tikrit, Iraq

ARTICLE INFO.

Article history:

-Received:

-Accepted:

-Available online:

Keywords

Deodorant blocker, Rat blood cells.

Corresponding Author:

Name: **Ayad Hameed**

E-mail:

dravadibrahim@gmail.com

Tel: **077017150182**

ABSTRACT

Twenty Rats were used in the present study to evaluate the effect of the deodorant blocker on the blood cells of the rat including the white blood cells and red blood cells. The animals were distributed into Group A control Five Rats and Group B Five treated animals.

The animals were put in steel cages in the animal house of veterinary medicine college. water with food free putto animals the skin of whole animals was shaved at the dorsum and at the flank region, then deodorant blocker was applied daily by whipping those areas for 30 days continuously, otherwise the control group was applying the distill water on the shaved areas. After the end of the experiment, a drop blood from the tip of tail was obtained and spread on the slide for staining by Leishman stain.

The results of blood examination were indicated release of the lymphocytes and monocytes percentage in comparison of control, also the certain number of RBCs indicated macrocytic, microcytic, incomplete hemoglobin ring and target cells as deformities of RBCs. In conclusions; the deodorant blocker induced imitation of immune system via increase the number of lymphocytes and monocytes which consider as main factors for immune response in cases of extrinsic insults.

1. Introduction

Deodorants are formulated to eliminate odor, they are typically alcohol – based when applied, they turn the skin acidic which make the skin less attractive to bacteria [1]

Aluminum is temporally blocking sweat glands [2]. Research by [3] showed that some ingredients used in deodorant are absorbed and stored in fat cells [3]. Benzene a known cancer-causing chemical was found in over half deodorant body spray and the exposure can be dangerous by increasing the risk of developing leukemia and other blood disorders [4].

Revealed that the toxins included within deodorant, like aluminum accumulate in the lymph nodes and chain healthy cells into cancer cells, so breast cancer develop in areas that are exposed to antiperspirants. other chains involve deodorants causing kidney diseases and allergies [5].

2. Materials and Methods

Ten albino rats were used in the present study weighing (150-200 gm) at age 6 – 12 months, those animals were housed in the animal house of veterinary medicine. the food and water were free for those animals and put in steel cages of 30x 20x15 cm dimensions., The animals were distributed into two groups. Group (A) Five animals (control) and Group (B) Five treated animals.

The whole Rats were shaved Their skin at the dorsal and flank areas, distill

water was applied to whipping the skin of Group (A) daily for 30 days continuously. The second Group (B) was whipping the shaved skin by deodorant blocker as a soap for 30 days continuously too. After the end of experiment, the tip of tail from whole animals was injured by needle after cleaning the tail by 70% alcohol. Drop of blood from each animal was obtained and spread on a class slide by the aid of other slide and remained until dry the whole slides were stained by Leishman's stain, according to [6].

The blood smears were examined under light microscope at power 1000 by oily and eye lenses. The blood examination was included the measuring the percentage of each type of white blood cells and morphology of red blood cells in comparison to normal values of control group.

3. Results and discussion

The gross inspection for the animals treated with deodorant blocker demonstrated an excitation after few minutes of whipping and rest after few minutes, also redness of the skin was seen, the animals were trying to itch by their mouth on the shaved skin, and for many days from this phenomenon, otherwise the activity and food intake was normal.

Examination the percentage of white blood cells was indicated the increase the number of lymphocytes and monocytes in comparison to that of control (Tables 1) and (Tables 2)

Table 1: Percentage of each white blood cell of treated rats

100%	Basophil	Eosinophil	Neutrophil	Monocyte	Lymphocyte	No.
100%	1	11	38	16	34	1
100%	0	4	40	14	42	2
100%	1	17	32	17	33	3
100%	1	8	45	15	31	4
100%	1	10	33	11	45	5
100%	0.8	10	37.6	14.6	37	Mean

Table 2: Percentage of each white blood cell of control group

Basophil	Eosinophil	Neutrophil	Monocyte	Lymphocyte
1	19	38	12	30

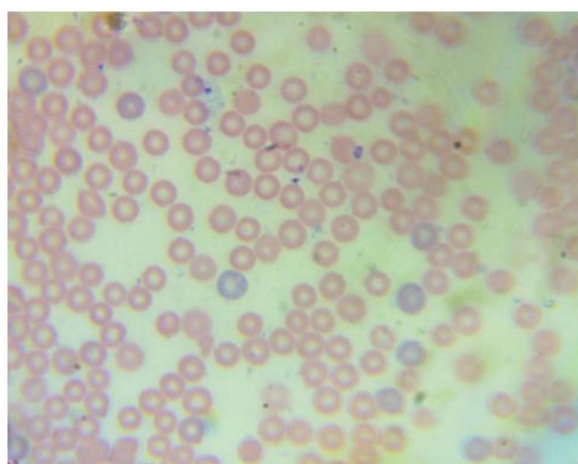


Fig (1). blood smear of group (A) showing red blood cells (X100).

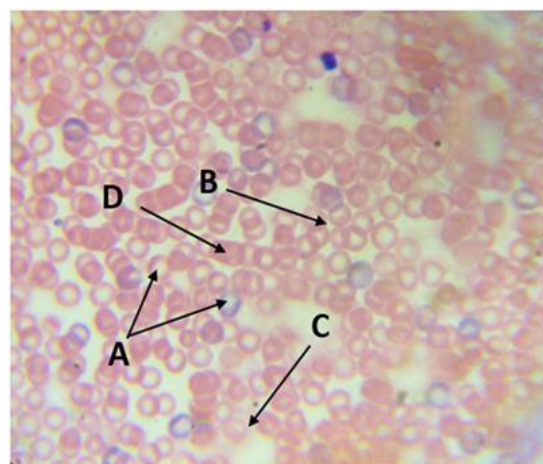


Fig (2) blood smear of group B, Incomplete hemoglobin ring(a) Microcyte(b), ghost cell(c), Macrocytes (d) X100.

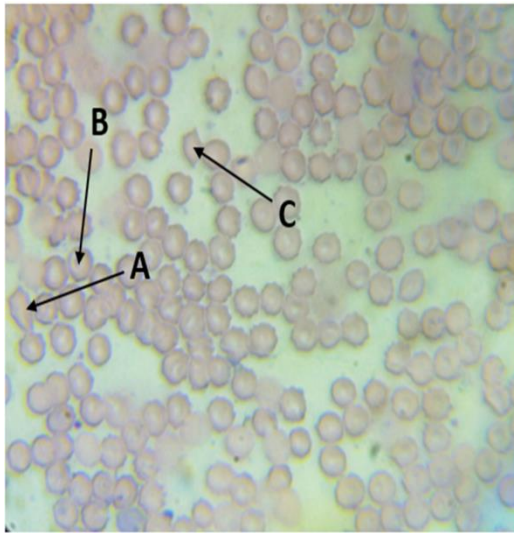


Fig (3). Group B, pear shape RBC (a). Target cell (b). RBC with spine(c)

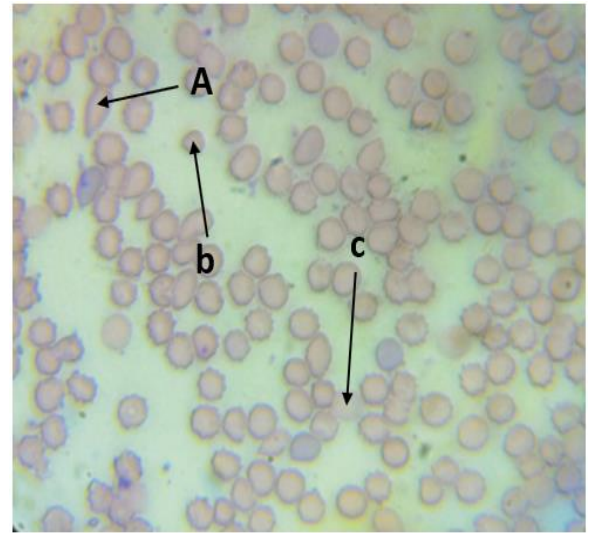


Fig (4): - group B. ovalocyte (a). Microcyte(b) Ghost cell(c) X100

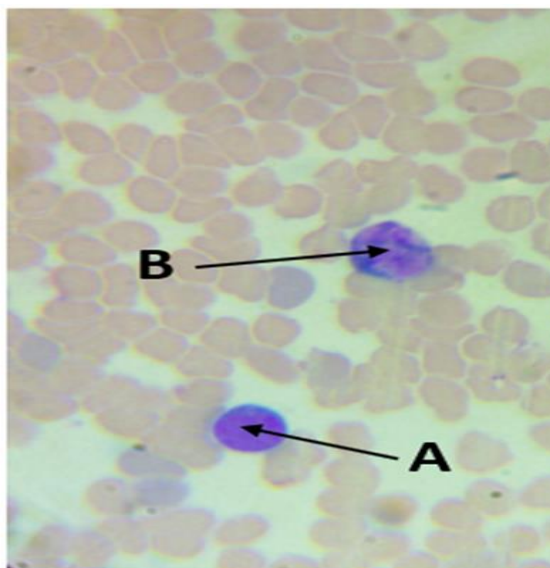


Fig (5):- group B, Lymphocyte (a), Monocyte (b), normoblast(c), crescent shape RBC (d) X100

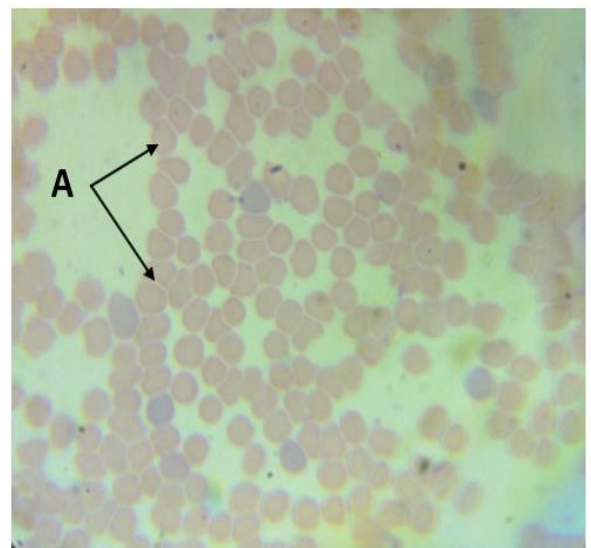


Fig (6): - Group A, Rolex phenomena (a) X100

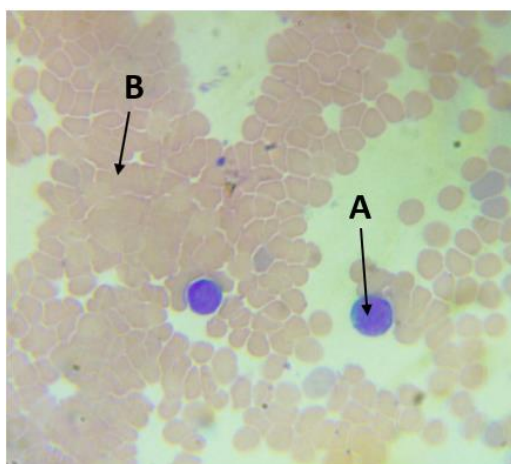


Fig (7): - Group A, Lymphocytes(a), RBCs mass(b)X100

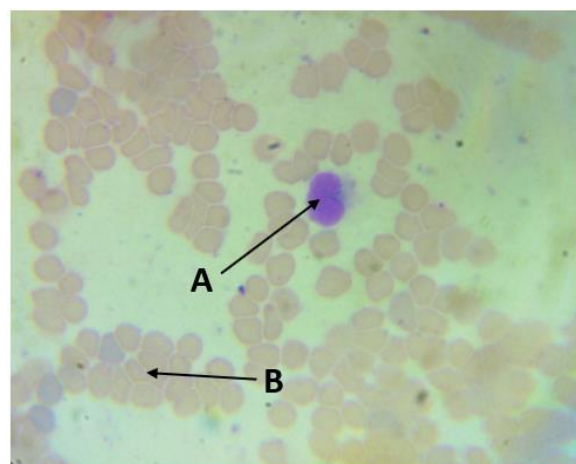


Fig (8): -Monocyte (A) of group B, RBCs (B) X100

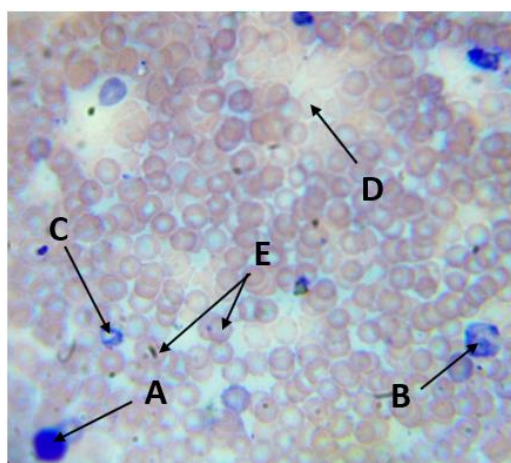


Fig (9): -Group B, Lymphocyte(a), Neutrophil (b), Incomplete ring of Hb(c), ghost cell(d), Target cell(e) X100

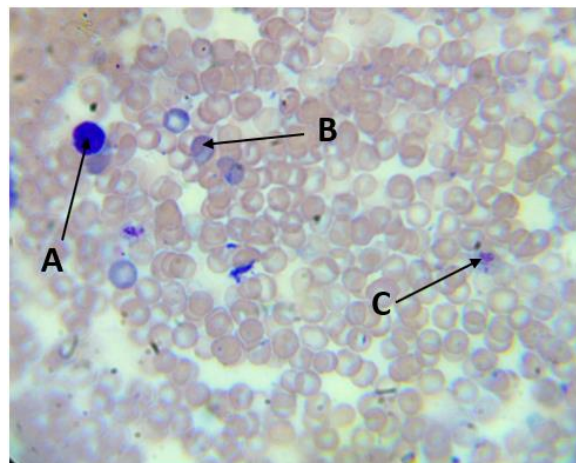


Fig (10): - Lymphocyte of group B (a), Normoblast(b), Target cell (C) X100

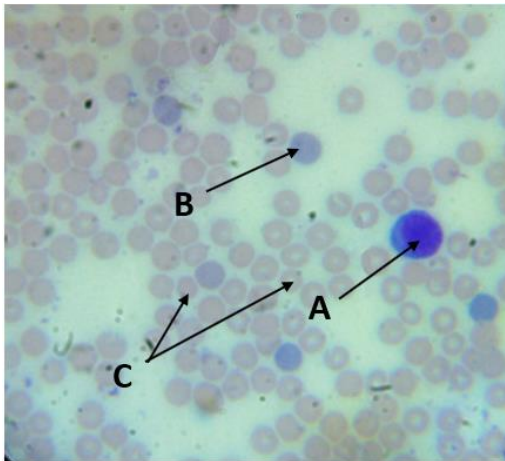


Fig (11): -Lymphocyte (a) of group (A), normoblast(b). microcyte(c) X100

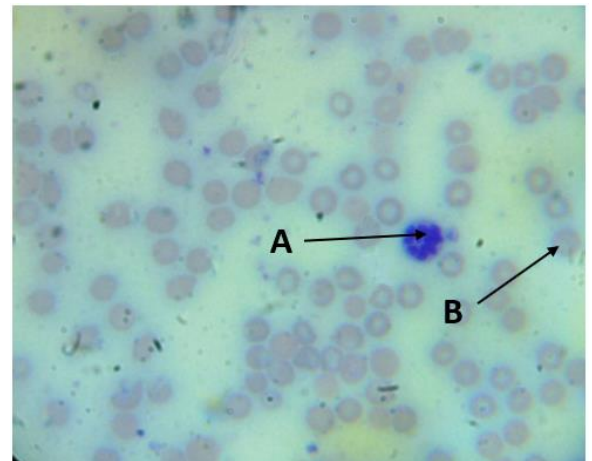


Fig (12): -group B, Basophil (a). Macrocyte (b) X100

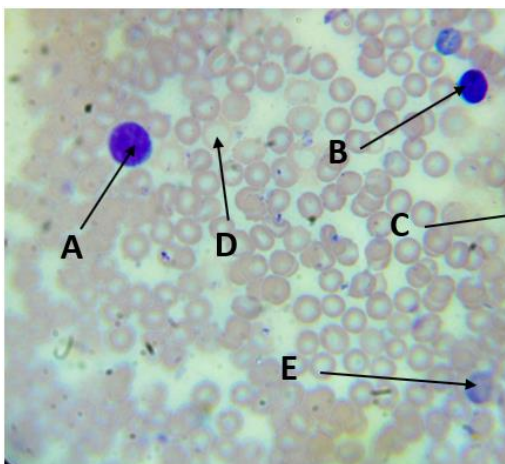


Fig (13): - Group B, Lymphocyte (a), small lymphocyte(b). normoblast (c), ghost cell (d), Macrocyte (e) X100

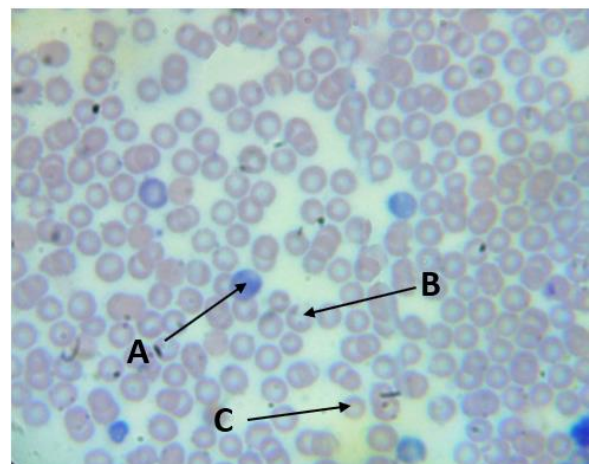


Fig (14):- group B, Normoblast (a), incomplete Hb ring (b) Microcyte (c) X100

The present study indicated that the lymphocytes were increased in its number and the mean was 37% while the control was 30% also the monocytes were 14.6% while in control was 12%, these results indicate that the immune system which represented by those types of cells was initiated for immune response due to reactive insult represented by application of antiblocker deodorant for one month continuously. This fact was referred by [7] that, it is possible of harmful effect on the blood cells, also they said that carcinogenic effect of aluminum which consider as a part of anti-deodorant ingredient has not been proven to date, but it is possible that critical internal exposure levels are present from this element in the concentration of blood and urine. Other white types of blood cells were not elevated, so consider not be significant release.

The present study, was indicated that examining the morphology of red blood cells is that certain cells were abnormal in its shape like macrocytic cells and microcytic, also found red blood cells with incomplete hemoglobin ring, and other cells had hemoglobin just in the central pallor, called target cells, as well as crescent cells and ghost red blood cells were indicated, according to that data which are documented by investigators a few information which are mentioned or referred to the effect of deodorant blocker on the blood [8], but mentioned to the effect of deodorant blocker on the brain that induce Alzheimer disease [9] and induction of breast cancer due to accumulation of aluminum salts in the tissue of mammary gland and fat cells [10].

Conclusion

In the conclusion application of the deodorant blocker as stick and whipping the shaved skin of rat for thirty days continuously revealed that allergic case for the animals and redness of shaved skin were inspected and the blood smears from the treated animals indicated the elevation in the lymphocytes correlated with monocytes, also certain abnormal shapes of red blood cells were indicated although their shapes were few.

Reference

- (1) Pierard, G.E., Elsner., Marks, R and Masson (2003): Guidance for the efficacy assessment of antiperspirants and deodorants. *Skin Pharmacol. Appl. Skin Physiol.* 16: 324 – 42.
- (2) Flarend, R.B., Elmore, D and Hem, SL (2001): A preliminary study of the dermal absorption of aluminum from antiperspirants using aluminum. *Food Chem. Toxicol.* 39: 163-168.
- (3) Katrin, K., Wobbeke, W., Frank, N and Andrea, H (2017): The health effect of aluminum exposure. *Ditch. Artel Int.* 114 (39) 653-659.
- (4) Barger, am (2003): The complete blood cell counts a power full diagnostic too. *Vet. Clinic. Small animals.* 33:1207-1222.
- (5) Ogoshi, K., Yanega, S., Moriyama, T and Archi, H (1994): Accumulation of aluminum in cancers of the liver, stomach, duodenum and mammary gland of rat. *Trace Elem. Electrolytes Health Disease* 8: 27-31.
- (6) Bancoft, J and Dandy stevens (1987): *Theory and practice of*

- histologic technique. Edinburgh Churchill Livingstone.
- (7) Bedoux, G., Rogi, B., Thomas, D and DuPont, L (2012): Occurrence and toxicity of antimicrobial triclosan and by - products in the environment. Environ. Sci. Pollute. Res. Int. 19: 1044 – 1065.
- (8) Shi, C and Pamir, Eg (2011): Monocyte recement during infection and inflammation. Nat. rev. Immunol. 11: 762- 774.
- (9) Wang, Z., Wei, X and Yang, J (2016): Chronic exposure to aluminum and risk of Alzheimer disease. A meta-analysis. Neurosci. Lett. 610: 200 -206.
- (10) Mc Garth, KG (2003): An earlier age of breast cancer diagnosis related to more frequent use of antiperspirants deodorants and under arm shaving. Eur. J. cancer prev. 12: 479 - 485.

التقييم النسيجي لتأثير صادرات العرق على خلايا الدم في الجرذان

أياد حميد ابراهيم¹، فراس عباس¹، ايناس مهند²

¹ فرع التشريح والانسجة كلية الطب البيطري ، جامعة تكريت، تكريت، العراق.

² المستشفى التعليمي البيطري، تكريت، العراق.

الملخص

عشرون جرذ استخدمت في هذه الدراسة الحالية لتقييم تأثير صادرات العرق على خلايا الدم في الجرذ وشملت خلايا الدم البيض والحمرة وزعت الحيوانات الى مجموعتين مجموعة A وهي مجموعة السيطرة (٥ جرذان) ومجموعة B المعالجة (٥ جرذان) وضعت الحيوانات في أقفاص حديدية في البيت الحيواني في كلية الطب البيطري واعطيت الماء والغذاء بشكل حر. جلد الحيوانات حلق في منطقة الظهر ومنطقة الخصرة ثم وضع صادرات العرق يوميا على هذه المناطق بشكل مسح لمدة ثلاثون يوماً متوالياً من ناحية اخرى مجموعة السيطرة تم مسح مناطق المحلقة بالماء المقطر يوميا. بعد انتهاء التجربة اخذت قطرة دم من نهاية الذيل وتم مسحها على الشريحة الزجاجية لتجف ثم صبغت بصبغة الشمان.

نتائج الدراسة بينت وجود زيادة بأعداد الخلايا اللمفية وخلايا وحيدة النواة بالمقارنة مع مجموعة السيطرة كذلك خلايا الدم الحمراء ظهر فيها خلايا كبيرة الحجم، صغيرة الحجم نقص في الهيموغلوبين ووجود خلايا هدفية التي مثلت عيوب في شكل خلايا الدم الحمراء. يستنتج من هذه الدراسة ان صادرات العرق احدثت زيادة في فعالية الجهاز المناعي من خلال ارتفاع اعداد الخلايا اللمفية ووحيدة النواة والذي يؤشر الى اعتبار هذه عوامل رئيسية للاستجابة المناعية في حالات وجود العوامل الخارجية المؤذية